

# Intravitreal injections using a novel conjunctival mould: a comparison with a conventional technique

Gokulan Ratnarajan, Remin Nath, Shivashankar Appaswamy, Sarah-Lucie Watson

Royal Berkshire Hospital,  
London Road, Reading, RG1  
5AN, UK

## Correspondence to

Dr Gokulan Ratnarajan, Royal  
Berkshire Hospital, London  
Road, Reading, RG1 5AN, UK;  
g.ratnarajan@gmail.com

This work has been presented  
at the EURETINA Congress in  
September 2012.

This work should be attributed  
to the Royal Berkshire Hospital,  
Reading, Berkshire, UK where  
all the work was completed.

Accepted 29 August 2012

## ABSTRACT

**Aims** The aims were to compare a novel conjunctival mould used to assist the delivery of intravitreal drugs to a conventional technique with respect to patient, surgeon and cost benefit.

**Methods** A prospective review of 200 intravitreal injections was undertaken, 100 using a 'conventional' freehand technique (group 1) and 100 using a novel conjunctival mould (group 2). Intraoperative visual analogue scale (VAS) pain scores, patient preference, surgeon perception of the ease of insertion of the conjunctival mould were recorded as well as a cost comparison.

**Results** VAS pain score in the conventional group was 2.58 compared to 1.38 in the conjunctival mould group ( $p < 0.01$ ). The surgeon reported the insertion of the conjunctival mould as easy in 89 cases, moderate in 10 cases, and difficult in one case. The cost saving with a conjunctival mould pack compared to a conventional pack was £7.70; an annual saving of £19 250 for the trust.

**Conclusions** The reduction in the VAS pain score with the conjunctival mould was statistically significant ( $p < 0.01$ ). The surgeons found that the device, which was easy to insert, offered excellent globe stability and a safe, reproducible entry site and angle of needle insertion.

## INTRODUCTION

Intravitreal injections are currently the treatment of choice for neovascular age-related macular degeneration,<sup>1 2</sup> and are also increasingly being used in the treatment of retinal vein occlusion and diabetic retinopathy.<sup>3-6</sup> This may provide a greater challenge for service provision in overloaded medical retina clinics and theatre lists.

It is widely accepted that the conventional method of administering intravitreal medications is safe.<sup>7 8</sup> It has been demonstrated that topical anaesthesia is as effective as subconjunctival anaesthesia with fewer side effects.<sup>9 10</sup> To the authors' knowledge there are no comparative studies assessing pain perception using a conjunctival mould against a conventional technique.

A clear conjunctival fixated mould has been designed called InVitria (FCI Ophthalmics, Massachusetts, USA) (figure 1). It is made of makrolon (Sheffield Plastics/Bayer, Leverkusen, Germany), a polycarbonate. It has a guide tube, which is designed to be 3.50 mm beyond the limbus and is angulated at 28° with a fixed depth of needle insertion to 5.60 mm. A position line for precise orientation with the limbus allows accurate placement of a 30 G needle with respect to site, angle and depth

when fully inserted into the guide tube both for phakic and pseudophakic eyes.

We investigated this new device as a means of simplifying the surgical procedure requiring less surgical dexterity, and reducing cost without compromising patient satisfaction or safety.

## MATERIALS AND METHODS

A prospective review of 200 patients receiving intravitreal injections for age-related macular degeneration was undertaken, with the first 100 patients (group 1) receiving the injection with a conventional freehand technique, and the second 100 patients (group 2) receiving the injection with the aid of a conjunctival mounted mould. No formal randomisation was carried out. Patient consent was gained and trust ethics approval was obtained.

## Data collected


For both groups, the intraoperative visual analogue scale (VAS) pain scores (see figure 2) were recorded, whether this was their first intravitreal injection, which eye, lens status and any operative complications or comments were recorded. The surgeon's perception of the ease of insertion of the device or speculum was noted in addition to the patient's preference of device if this was not their first injection.

## Surgical procedure

A drape was applied and an open-wire eyelid speculum was only inserted for the conventional treatment group as recommended by the Royal College of Ophthalmologists intravitreal injections procedure guidelines.<sup>11</sup> In the conventional group, 0.5 mg ranibizumab in 0.05 ml was delivered with a 30 G needle, 3.5 mm or 4 mm from the limbus in pseudophakic and phakic patients, respectively. In the conjunctival mould group, all were given injections 3.5 mm from the limbus. In the conventional group, conjunctival displacement was performed with forceps and tamponade applied to the injection site immediately after needle withdrawal to prevent vitreous prolapse through the needle track. In the conjunctival mould group a small rotation of the mould was carried out before needle insertion and on needle withdrawal with slight application of pressure to prevent vitreous prolapse.

## Pain evaluation

A VAS with numerical and descriptive ratings from 0 (no pain) to 10 (unbearable pain), was used to standardise pain (figure 2). A nurse, specifically trained for the study, asked each patient to grade



**Figure 1** The key beneficial design features of the conjunctival mould to assist in intravitreal injections. (1) The open top design allows for centration on to the cornea by direct visualisation. (2) The flange prevents eye lashes and the eyelid margin from coming into contact with the wound. (3) The base enables conjunctival displacement over the entry site with simple rotation and stabilisation of the globe. No speculum or drape is required.

his or her level of pain or discomfort according to the VAS following the intravitreal injection.

**RESULTS**  
**VAS score**

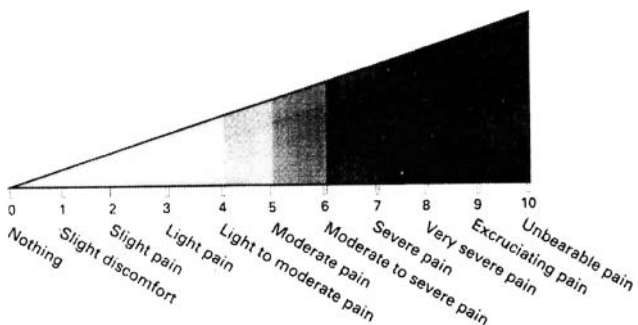
The intraoperative VAS pain score in group 1 was 2.58 (range 0–10) compared to 1.38 (range 0–7) in group 2 ( $p < 0.01$ , these were not corrected for multiple testing and so should be viewed as nominal) (figure 3).

**Patient comparison between the two techniques**

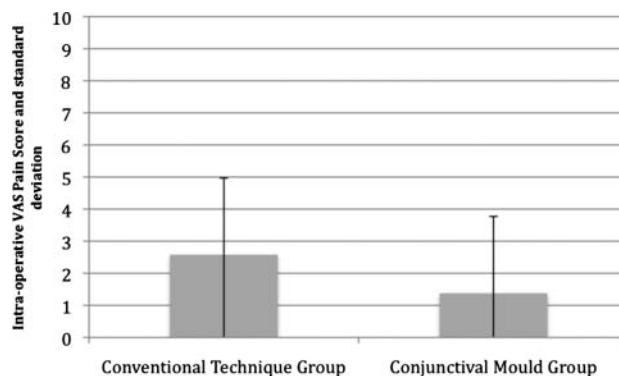
Of the 84 patients in group 2 who had previously had an intravitreal injection using the conventional technique, 42 (50%) found the conjunctival mould method less painful, with a further 36 (43%) reporting no noticeable difference in pain perception, and only six (7%) patients found it more painful.

**Surgeon feedback**

Ease of insertion of the conjunctival mould was reported as ‘straightforward’ in 89 cases, ‘moderate’ in 10 cases and ‘difficult’ in one case.



**Figure 2** Visual analogue pain scale.



**Figure 3** Intraoperative visual analogue scale (VAS) pain score for the conventional technique and conjunctival mould group.

**Operative complications and comments**

In group 1 subconjunctival haemorrhage was noted six times. In group 2 there were two cases of subconjunctival haemorrhage. The surgeon documented that two patients were squeezing their lids excessively during mould insertion. For these two patients the surgeon recorded ease of insertion of the mould as difficult in one and moderate in the other.

**Cost analysis**

A conventional pack contains a surgical drape, lid speculum, callipers, disposable Moorfields forceps, two gallipots, gauze and gauze holders, tray cover and needle disposal block. The alternative pack contains a conjunctival mould, two gallipots, gauze and gauze holders. Using local procurement figures, there was a saving of £7.70 per patient when the conjunctival mould and associated pack was used. For the Royal Berkshire Hospital Foundation Trust, which carries out approximately 2500 intravitreal injections per year, this translates to an annual saving of £19 250.

**DISCUSSION**

**Patient benefit**

This prospective study has demonstrated a statistically significant reduction in pain perception when using a conjunctival mould compared to a conventional technique of intravitreal injection. It has been suggested it may be related to the fact that when the mould is placed over the entire circumference of the limbus a blunt but firm pressure is experienced. This may act as physical anaesthetic block to the ciliary nerves. Patients also preferred not having a drape placed over them.

**Surgeon benefit**

The conjunctival mould offers greater globe stability and reproducibility of entry site position and angle facilitating a consistent, safer technique. Furthermore, the conjunctival mould simplifies the surgical skill required to perform the safe intravitreal delivery of a drug for a less experienced surgeon. There was no evidence of any difference in the complication rates such as retinal detachment and endophthalmitis using this device in our small study.

**Economic benefit**

The use of the conjunctival mould resulted in a saving of £7.70 per patient, translating to a potential annual saving in this trust of £19 250.

The overall time required to perform the procedure is shorter with the mould and therefore more injections can be performed in a session, thus providing further financial benefits to the trust, without compromising patient safety.

With the ever rising demand for intravitreal injections, questions have been raised as to the feasibility and safety of non-surgeons such as nurses or other allied health professionals performing the procedure. The answer to this question is beyond the scope of this paper; however, the authors' experience of this conjunctival mould is that it does simplify and standardise the surgical procedure and reduces both patient and surgeon-related variables, potentially making this a more user-friendly option for those not regularly performing/trained in intraocular surgery.

## CONCLUSION

The authors feel that the use of this conjunctival mould results in a reproducible, safer and more cost-effective method of delivering intravitreal drugs, although a larger study is needed to fully establish the clinical utility of this device.

Patients perceived it to be less painful than the conventional technique and its use has resulted in a substantial cost saving for the hospital trust.

**Acknowledgements** The authors would like to thank Gary Parker of FCI for the use of the photo of the device.

**Contributors** All authors for this paper fully comply with the ICMJE guidelines for authorship.

**Ethics approval** Ethics approval was obtained from the Royal Berkshire Hospital Foundation Trust.

**Patient consent** Obtained.

**Competing interests** None.

**Provenance and peer review** Not commissioned; externally peer reviewed.

## REFERENCES

1. **Rosenfeld PJ**, Brown DM, Heier JS, *et al.*, for the MARINA Study Group. Ranibizumab for neovascular aged-related macular degeneration. *N Engl J Med* 2006;**355**:1419–31.
2. **Brown DM**, Kaiser PK, Michels M, *et al.*, for the ANCHOR Study Group. Ranibizumab versus Verteporfin for neovascular aged-related macular degeneration. *N Engl J Med* 2006;**355**:1432–44.
3. **Brown DM**, Campochiaro PA, Singh RP, *et al.*, for the CRUISE Investigators. Ranibizumab for macular edema following central retinal vein occlusion: 6-month primary endpoint results of a phase III study. *Ophthalmology* 2010;**117**:1124–33.
4. **Campochiaro PA**, Heier JS, Feiner L, *et al.*, for the BRAVO Investigators. Ranibizumab for macular edema following branch retinal vein occlusion: 6-month primary endpoint results of a phase III study. *Ophthalmology* 2010;**117**:1102–12.
5. **Scott IU**, Ip MS, VanVeldhuisen PC, *et al.* A randomized trial comparing the efficacy and safety of intravitreal triamcinolone with standard care to treat vision loss associated with macular edema secondary to branch retinal vein occlusion: the Standard Care vs Corticosteroid for Retinal Vein Occlusion (SCORE) study report 5. *Arch Ophthalmol* 2009;**127**:1115–28.
6. **Rodriguez-Fontal M**, Alfaro V, Kerrison JB, *et al.* Ranibizumab for diabetic retinopathy. *Curr Diabetes Rev* 2009;**5**:47–51.
7. **Jager RD**, Aiello LP, Patel SC, *et al.* Risks of intravitreal injection: a comprehensive review. *Retina* 2004;**24**:676–98.
8. **Ta CN**. Minimizing the risk of endophthalmitis following intravitreal injections. *Retina* 2004;**24**:699–705.
9. **Cintra LP**, Lucena LR, Da Silva JA, *et al.* Comparative study of analgesic effectiveness using three different anaesthetic techniques for intravitreal injections of bevacizumab. *Ophthalmic Surg Lasers Imaging* 2009;**40**:13–18.
10. **Blaha GR**, Tilton EP, Barouch FC, *et al.* Randomized trial of anesthetic methods for intravitreal injections. *Retina* 2011;**31**:535–9.
11. Royal College of Ophthalmologists Clinical Guidelines. <http://www.rcophth.ac.uk/page.asp?section=451&sectionTitle=Clinical+Guidelines> (accessed 14 Sep 2012).